

Dexmedetomidine for anesthetic management of anterior mediastinal mass

Basem Abdelmalak · Nicholas Marcanthony ·
Joseph Abdelmalak · Michael S. Machuzak ·
Thomas R. Gildea · D. John Doyle

Received: 12 October 2009 / Accepted: 31 March 2010 / Published online: 8 May 2010
© Japanese Society of Anesthesiologists 2010

Abstract Anesthetic management of anterior mediastinal masses (AMM) is challenging. We describe the successful anesthetic management of two patients with AMM in which dexmedetomidine was used at supra-sedative doses. Our first case was a 41-year-old man who presented with a 10 × 9 × 11 cm AMM, a pericardial effusion, compression of the right atrium, and superior vena cava syndrome. He had severe obstruction of the right mainstem bronchus, distal trachea with tumor compression, and endobronchial tumor invasion. Our second case was a 62-year-old man with tracheal and bronchial obstruction secondary to a recurrent non-small-cell lung cancer mediastinal mass. Both patients were scheduled for laser tumor debulking and

treatment of the tracheal compression with a Y-stent placed through a rigid bronchoscope. Both patients were fiberoptically intubated awake under sedation using a dexmedetomidine infusion, followed by general anesthesia (mainly using higher doses of dexmedetomidine), thus maintaining spontaneous ventilation and avoiding muscle relaxation during a very stimulating procedure. The amnestic and analgesic properties of dexmedetomidine were particularly helpful. Maintaining spontaneous ventilation with dexmedetomidine as almost the sole anesthetic could be very advantageous and may reduce the risk of complete airway obstruction in the anesthetic management of AMMs.

Keywords Mediastinal mass · Dexmedetomidine · Airway management

B. Abdelmalak
Section of Anesthesia for Bronchoscopic Surgery,
Departments of General Anesthesiology and Outcomes
Research, Anesthesiology Institute, Cleveland Clinic,
Cleveland, USA

N. Marcanthony · J. Abdelmalak
Anesthesiology Institute, Cleveland Clinic, Cleveland, USA

M. S. Machuzak
Center for Major Airway Disease, Respiratory Institute and
Transplant Center, Cleveland Clinic, Cleveland, USA

T. R. Gildea
Section of Bronchoscopy, Respiratory Institute and Transplant
Center, Cleveland Clinic, Cleveland, USA

D. J. Doyle
Department of General Anesthesiology,
Anesthesiology Institute, Cleveland Clinic, Cleveland, USA

B. Abdelmalak (✉)
Department of General Anesthesiology/E31, Cleveland Clinic,
9500 Euclid Avenue, Cleveland, OH 44195, USA
e-mail: abdelmb@ccf.org

Introduction

The anatomical position of an anterior mediastinal mass within the thorax can predispose patients to severe respiratory and/or cardiovascular complications during anesthesia. These may include airway obstruction, compression of cardiac chambers, and/or compression of the pulmonary artery. We describe the successful anesthetic management of two patients with anterior mediastinal masses (AMMs) in which spontaneous ventilation was achieved with minimum respiratory depression by using dexmedetomidine at supra-sedative doses.

Case 1

The patient was a 41-year-old man with synovial cell carcinoma of the left lower leg complicated by pulmonary

metastasis. He had previously undergone a right upper lobe (RUL) resection, a left lower lobectomy, and chemotherapy. As his disease progressed he developed a $10 \times 9 \times 11$ cm AMM (Fig. 1a, b), a pericardial effusion, multiple deep venous thromboses, pulmonary emboli, chronic airway obstruction, compression of the right atrium, and superior vena cava syndrome. He had severe obstruction of the right mainstem bronchus with tumor compression from the residual RUL. There was also extrinsic compression of the distal trachea and endobronchial tumor invasion of the remaining right lung, so he was ventilating from the left upper lobe and lingula only. The patient was very symptomatic, being short of breath with minimum activity, and his functionality was severely affected.

The plan was laser debulking of the tumor of the right lower and middle lobes and treatment of the compression with a Y-stent with a short left-sided limb.

Case 2

This patient was a 62-year-old man who initially presented a year before this procedure with shortness of breath and cough and was diagnosed with T4 N0 M0 tracheal cancer. He underwent initial laser debulking followed by chemotherapy (carbo-taxol), external beam radiation (5,940 cGy in 33 fractions), and brachytherapy application, with further brachytherapy 4 months later.

He remained well for two months when he noted progressively worsening shortness of breath, cough, hemoptysis, and wheezing. This led to a repeat CT scan (Fig. 2a, b), which demonstrated recurrence of the tracheal cancer with paratracheal mediastinal adenopathy. The tumor was judged to be unresectable locally and he was transferred to our tertiary care facility for further treatment. He was scheduled for bronchoscopic debulking and stenting.

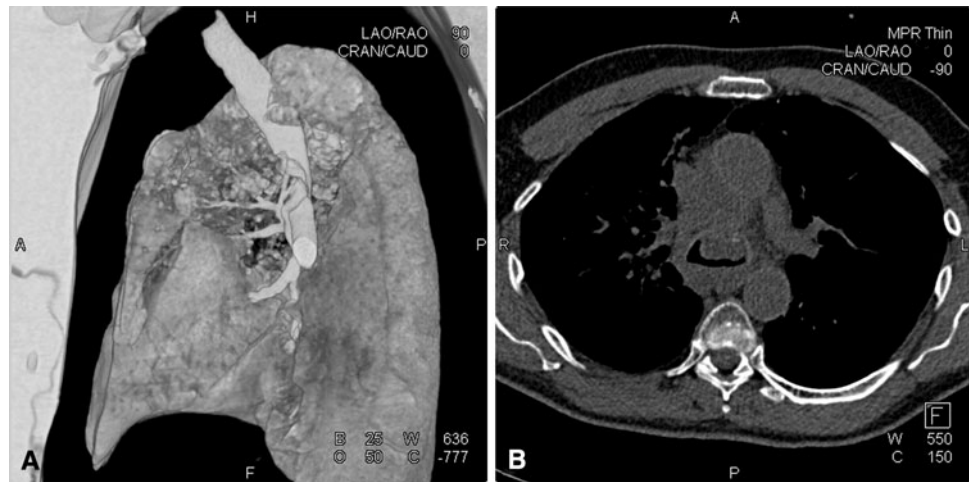
Anesthetic management

Both patients were premedicated with 2 mg IV midazolam, followed by dexmedetomidine 1 mcg/kg IV infusion over 10 min as a loading dose and 0.6 mcg/kg/h to maintain sedation. The airway was topicalized with atomized lidocaine 4%. Following awake fiberoptic intubation with an 8.0 endotracheal tube (ETT), the dexmedetomidine infusion was gradually increased towards anesthetic levels (up to five times the maximum recommended dose for sedation; 0.2–0.7 mcg/kg/h). Small amounts of isoflurane (0.3%) for patient #1 and approximately 1.0% sevoflurane for patient #2 were also added. Adequate surgical anesthesia was assured by monitoring the patient's movements in response to surgical stimulation and by using a BIS[®] monitor (Aspect Medical, Newton, MA, USA) where the BIS index was maintained between 40 and 60. Both patients maintained spontaneous ventilation throughout, sustaining adequate oxygenation. No muscle relaxant was used. Intraoperative arterial blood gas analysis for the second patient during the early phase of his surgery while on 100% FiO₂ showed pH of 7.42, PaCO₂ of 44.3 mmHg, PaO₂ of 199 mmHg, BE of 4 mmol/L, sodium bicarbonate of 28.5 mmol/L, and O₂ saturation of 97%. The tumor was lasered via a flexible bronchoscope with the FIO₂ kept at approximately 30%. The ETT was then removed and a rigid bronchoscope was used for placement of the Y-stent and, in patient #2, further tumor debulking in a coring fashion using the barrel. Following successful stent placement, a tube exchanger was then introduced through the rigid bronchoscope and a 7.5 Parker ETT was railroaded over it after removal of the rigid bronchoscope. Our second patient had three episodes when his blood pressure fell from starting values of 120/60 mmHg to 80 s/50 s mmHg that was treated successfully with a bolus of 100 mcg of phenylephrine administered intravenously. On conclusion

Fig. 1 Patient # 1: **a** A volume-rendered 3D CT image in which the *black space* represents the mediastinal mass showing the effect on the airway. **b** CT showing the size of the calcified anterior mediastinal mass with lateral displacement and tracheal compression

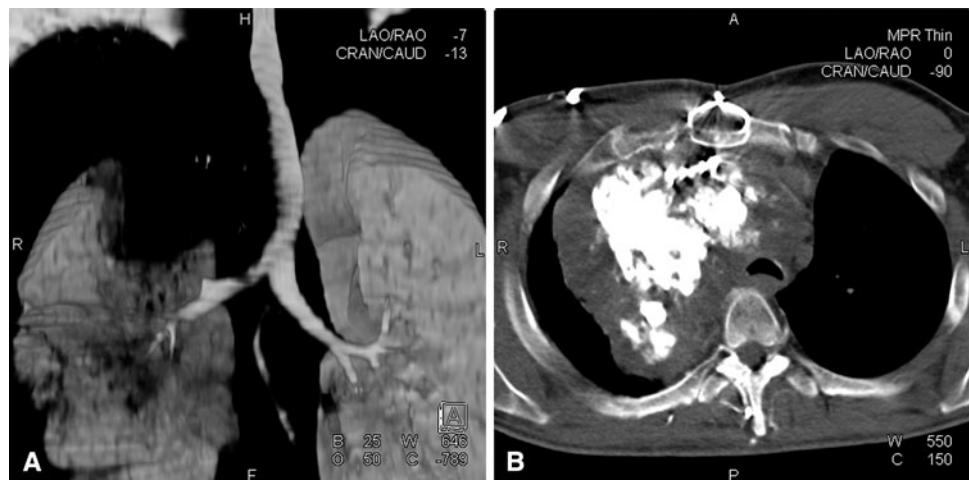

Fig. 2 Patient # 2: **a** A volume-rendered 3D CT image showing the same (note what is left of the tracheal lumen after removal of the mediastinal mass from the image). **b** CT showing the size of the anterior mediastinal mass with tracheal compression (note the very small flattened tracheal lumen) and right main stem bronchus intrusion



of the procedure, the patients were transported to the post-anesthesia care unit (PACU) on a T-piece circuit supplied with 15 L/min of oxygen while breathing spontaneously. Both were extubated about 30 min after arriving in the PACU and reported no recall.

Discussion

We report the first successful use of dexmedetomidine as almost sole anesthetic without muscle relaxation in the management of a massive anterior mediastinal mass.

It has long been established that AMMs can precipitate serious, life-threatening respiratory and cardiovascular events [1]. The incidence of such complications in a pediatric population is approximately 7–20% intraoperatively and approximately 18% postoperatively [2–6]. Because these were observations made in a pediatric population, it is difficult to project this into the adult population [7]. However, extreme caution is advised in similar adult scenarios.

Airway obstruction is a very real and dangerous complication of general anesthesia in patients with an AMM. Three reasons have been given for this [8]. First, lung volumes can be reduced to 0.5–1.0 L, reducing oxygen stores. Second, general anesthesia relaxes airway smooth muscle leading to increased compliance, thus making it more likely to collapse under the pressure of the tumor. Finally, loss of spontaneous diaphragm movement precipitates a decrease in transpleural pressure gradient leading to a decrease in airway diameter. These factors all facilitate tumor compression of the airway. If use of muscle relaxants is avoided, spontaneous ventilation counteracts these mechanisms and maintains the negative intra-pleural pressure. This has been highly recommended in the anesthetic management of AMM patients [9].

Intraoperative management can be extremely difficult in patients with an AMM; a number of different conservative anesthetic management plans have been suggested [10]. The patient should be intubated via awake fiberoptic techniques with sedation while in the least symptomatic position. Topical anesthesia and inhalational agents are both good adjunctive courses of action.

Sedation, as an anesthetic technique, was not an option in this case because of the need to use a rigid bronchoscope to insert the plastic Y-shaped stent for tracheobronchial support at the carinal level. We decided to proceed with awake intubation followed by general anesthesia using dexmedetomidine which, even at higher doses, allowed spontaneous ventilation.

Dexmedetomidine is a selective α_2 agonist with sedative, analgesic, amnestic [11], and antisialagogue properties [12] that maintain spontaneous respiration with minimum respiratory depression, making it quite suitable for such cases. It is administered intravenously, the preferred route for anesthetic delivery in bronchoscopic surgery. Patients under dexmedetomidine sedation are usually easy to arouse [13], a property we exploited during awake fiberoptic-assisted intubation [14].

To maintain adequate anesthesia during a very stimulating procedure we used a relatively large dose of dexmedetomidine (compared with the sedation dose range of 0.2–0.7 mcg/kg/h); this is considered to be an off-label use. Such a large dose, or even larger, up to ten times the maximum recommended sedation dose, has been reported by Ramsay et al. as sole anesthetic agent in the anesthetic management of complicated clinical challenges [15], albeit in different circumstances in less stimulating procedures, and mainly to avoid the use of supplemental oxygen that could have increased surgical risk. In addition, low concentrations of isoflurane in the first case and sevoflurane in the second case were used to complement the limited

amnesic properties of dexmedetomidine [11]. At this dose neither isoflurane nor sevoflurane induced sufficient muscle relaxation to adversely affect respiratory function. It should be noted that many authorities recommend the use of sevoflurane in preference to isoflurane in similar situations, because it is claimed to cause less airway irritation.

The same line of thinking appealed to Ramsay et al. [16] when they used an anesthetic composed of 5 mg midazolam, dexmedetomidine infusion (up to 10 mcg/kg/h), and 1.0% sevoflurane in the anesthetic management of tracheal stenosis. Similarly, Nafiu et al. [17] used dexmedetomidine infusion as a sedative for a patient with a mediastinal mass undergoing Chamberlin's procedure.

Clinicians intending to use dexmedetomidine must be aware of its side effects. Those few side effects which are an extension of its pharmacological actions have been reported to be increases in systemic and pulmonary vascular resistance and hypertension (induced by peripheral α -2B receptors) when high doses are infused rapidly. Also, hypotension, bradycardia, and decreased cardiac output are evident at concentrations twofold greater than the therapeutic level. We encountered some hypotension with our second patient that was successfully treated with a small dose of phenylephrine. Thus, vigilant monitoring is essential when high doses of dexmedetomidine are used.

It has been suggested that cardiopulmonary bypass be available on stand-by and that femoral vessel cannulation should be achieved prior to induction for cases with patients having a >50% reduction in airway diameter, as seen on a computed tomography scan [2, 10]. However, some have noted that even having bypass equipment on stand-by will not always ensure a good outcome [9]. Even with a bypass team on standby, it may take from 5 to 10 min for adequate oxygenation to be achieved after complete airway obstruction [18]. Although the patient is most likely to be resuscitated, there is a good chance of hypoxic neurological injury. This emphasizes the importance of utilizing an anesthetic plan that lessens the chances of the need for such a very invasive intervention.

We conclude that maintaining spontaneous ventilation with dexmedetomidine as almost the sole anesthetic could be very helpful and may reduce the risk of complete airway obstruction in the anesthetic management of an AMM.

Acknowledgments Supported by internal funds. Dr Basem Abdelmalak receives a research grant from Aspect Medical (Newton, MA, USA) in support of other research projects.

Conflict of interest statement Dr. Abdelmalak recently received a one time honorarium from Hospira, Inc.

References

1. Bittar D. Respiratory obstruction associated with induction of general anesthesia in a patient with mediastinal Hodgkin's disease. *Anesth Anal.* 1975;54:399–403.
2. Azizkhan RG, Dudgeon DL, Buck JR, Colombani PM, Yaster M, Nichols D, Civin C, Kramer SS, Haller JA Jr. Life-threatening airway obstruction as a complication to the management of mediastinal masses in children. *J Pediatr Surg.* 1985;20:816–22.
3. King DR, Patrick LE, Ginn-Pease ME, McCoy KS, Klopfenstein K. Pulmonary function is compromised in children with mediastinal lymphoma. *J Pediatr Surg.* 1997;32:294–9.
4. Piro AJ, Weiss DR, Hellman S. Mediastinal Hodgkin's disease: a possible danger for intubation anesthesia. Intubation danger in Hodgkin's disease. *Int J Radiat Oncol Biol Phys.* 1976;1:415–9.
5. Ferrari LR, Bedford RF. General anesthesia prior to treatment of anterior mediastinal masses in pediatric cancer patients. *Anesthesiology.* 1990;72:991–5.
6. Turoff RD, Gomez GA, Berjian R, Park JJ, Priore RL, Lawrence DD, Panahon A, Douglass HA Jr. Postoperative respiratory complications in patients with Hodgkin's disease: relationship to the size of the mediastinal tumor. *Eur J Cancer Clin Oncol.* 1985;21:1043–6.
7. Bechard P, Letourneau L, Lacasse Y, Cote D, Bussieres JS. Perioperative cardiorespiratory complications in adults with mediastinal mass: incidence and risk factors. *Anesthesiology.* 2004;100:826–34.
8. Neuman GG, Weingarten AE, Abramowitz RM, Kushins LG, Abramson AL, Ladner W. The anesthetic management of the patient with an anterior mediastinal mass. *Anesthesiology.* 1984;60:144–7.
9. Slinger P, Karsli C. Management of the patient with a large anterior mediastinal mass: recurring myths. *Curr Opin Anaesthesiol.* 2007;20:1–3.
10. Goh MH, Liu XY, Goh YS. Anterior mediastinal masses: an anaesthetic challenge. *Anaesthesia.* 1999;54:670–4.
11. Ebert TJ, Hall JE, Barney JA, Uhrich TD, Colino MD. The effects of increasing plasma concentrations of dexmedetomidine in humans. *Anesthesiology.* 2000;93:382–94.
12. Scher CS, Gitlin MC. Dexmedetomidine and low-dose ketamine provide adequate sedation for awake fiberoptic intubation. *Can J Anaesth.* 2003;50:607–10.
13. Maze M. Pharmacology and Use of Alpha-2 agonists in Anesthesia. *European Society of Anesthesiologists Refresher Course.* 2003; 37–43.
14. Abdelmalak B, Makary L, Hoban J, Doyle DJ. Dexmedetomidine as sole sedative for awake intubation in management of the critical airway. *J Clin Anesth.* 2007;19:370–3.
15. Ramsay MA, Luterman DL. Dexmedetomidine as a total intravenous anesthetic agent. *Anesthesiology.* 2004;101:787–90.
16. Ramsay MA, Saha D, Hebel RF. Tracheal resection in the morbidly obese patient: the role of dexmedetomidine. *J Clin Anesth.* 2006;18:452–4.
17. Nafiu OO, Srinivasan A, Ravanbakht J, Wu B, Lau WC. Dexmedetomidine sedation in a patient with superior vena cava syndrome and extreme needle phobia. *J Cardiothorac Vasc Anesth.* 2008;22:581–3.
18. Tempe DK, Arya R, Dubey S, Khanna S, Tomar AS, Grover V, Nigam M, Makwane UK. Mediastinal mass resection: femoro-femoral cardiopulmonary bypass before induction of anesthesia in the management of airway obstruction. *J Cardiothorac Vasc Anesth.* 2001;15:233–6.